

Glossopharyngeal neuralgia due to lacunar infarction of PICA: an unusual case

María E. Novoa M.¹ María Alfaro-Olivera¹
Instituto Nacional de Ciencias Neurológicas¹. Lima-Perú



OBJECTIVE:

We present an unusual case of GPN, secondary to a lacunar infarct in the p2-segment of the PICA.

INTRODUCTION

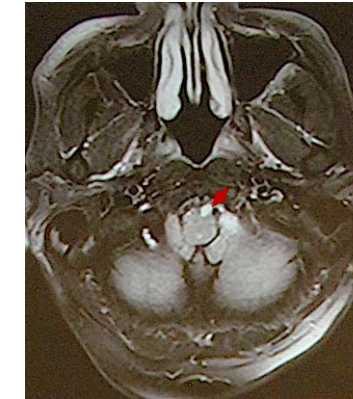
- Glossopharyngeal neuralgia (GPN) is of sudden onset, lasting seconds, usually caused by cold stimuli when chewing, swallowing, talking, coughing, yawning, and sneezing(1).
- Painful paroxysms are characteristic, located mostly in the oropharynx and irradiated to the middle ear or vice versa, due to involvement of the pharyngeal branch or auricular branch of the glossopharyngeal nerve (GN)(2).
- According to the ICHD-3 (International Classification of Headache Disease-3), classic GPN occurs due to vascular compression(3, 4). Secondary GPN, due to underlying disease; while idiopathic GPN has no causal evidence(5).
- Incidence of 0.7/100,000/year, 9:5 males over females, average age 64 years, left location, 12:9(6).
- Infarcts of the posterior inferior cerebellar artery (PICA), an unusual cause of GPN cause of GPN, involving small vessels, associated with risk factors, would explain the ischemic etiology.
- They represent 40% of cerebellar infarcts, compared to the anterior inferior cerebellar artery (AICA) and the superior cerebellar artery (SUCA)(7).
- The PICA is divided into 5 segments; anterior medullary (p1), lateral medullary (p2), tonsillomedullary (p3), telovelotonsillar (p4) and cortical (p5). Being, the lateral spinal cord segment (p2), the most involved(8). Represented by Wallenberg syndrome(9).
- T2weighted imaging (T2WI) is more sensitive than fluid-attenuated inversion recovery (FLAIR) in identifying posterior fossa infarcts(10, 11).

CASE DESCRIPTION

- 65-year-old male, with no apparent pathological history.
- He reports sudden oropharyngeal pain, radiating to the mandibular angle and left ear, as bursts of electric shocks between 7 and 10 seconds, 2 times a day, when chewing, swallowing and speaking.
- Concomitantly, dizziness and vertigo are limited to the week of onset of pain.
- Oropharyngeal tactile stimulation causes a burst of pain that paralyzes the patient for a few seconds.
- The T2 sequence (T2W1) of the MR showed a small hyperintensity in the lateral medullary segment of the left posterior inferior cerebellar artery (PICA).
- Uncontrolled arterial hypertension, cardiac arrhythmia and hypothyroidism were the risk factors found in the patient.
- Indicating pregabalin (75 mg/1 time/day) and the management of heart attack risk factors.

DISCUSSION

- The case presented did not characterize Wallenberg syndrome. However, it compromised the prominence of the bulbar olive, up to the origin of the rootlets of the GN, where the pharyngeal branch of the left GN could be injured(5, 12) and cause GPN.
- Meanwhile, the scant surrounding edema in the small ischemia would promptly explain the limited dizziness and vertigo.
- The theory of mechanisms of hyperexcitability and ephaptic transmission in central neurons, activating N-methyl-D-aspartic acid receptors in the GN(13).
- They would explain the efficacy of antiepileptic drugs in neuralgia.
- Pregabalin at minimal doses controlled the patient's outbursts of pain.



MRI T2W1 sequence showed small hyperintensity in left PICA-p2.

CONCLUSION

GPN of small infarct in the PICA territory is an unusual condition. In our case, the lateral anteromedullary segment of the left PICA compromised the ipsilateral GN. The T2W1 of the MR sequence revealed hyperintensity in PICA-p2. Management with pregabalin was effective.

REFERENCES

- 1.Cutri RM, Shukya D, Shibata SB. Neuralgia and Atypical Facial, Ear, and Head Pain. *Otolaryngol Clin North Am.* 2022;55(3):595-606.
- 2.Xia L, Li YS, Liu MX, Zhong J, Dou NN, Li B, et al. Microvascular decompression for glossopharyngeal neuralgia: a retrospective analysis of 228 cases. *Acta Neurochir (Wien).* 2018;160(1):117-23.
- 3.Yonekawa Y. [Operative neurosurgery: personal view and historical backgrounds (7) reappraisal of approaches]. *No Shinkei Geka.* 2010;38(11):1031-45.
- 4.Manohar N, Palan A, Balasubramaniam A, Boyina RJ. Novel Use of Glossopharyngeal SSEP in Microvascular Decompression for Glossopharyngeal Neuralgia. *Neuro India.* 2022;70(1):422-3.
- 5.Headache Classification Committee of the International Headache Society (IHS) The International Classification of Headache Disorders, 3rd edition. *Cephalalgia.* 2018;38(1):1-211.
- 6.Manzoni GC, Torelli P. Epidemiology of typical and atypical craniofacial neuralgias. *Neurol Sci.* 2005;26 Suppl 2:s65-7.
- 7.Miao HL, Zhang DY, Wang T, Jiao XT, Jiao LQ. Clinical Importance of the Posterior Inferior Cerebellar Artery: A Review of the Literature. *Int J Med Sci.* 2020;17(18):3005-19.
- 8.Nickel A, Cheng B, Pinn Schmidt H, Arpa E, Ganos C, Gerloff C, et al. Clinical Outcome of Isolated Cerebellar Stroke-A Prospective Observational Study. *Front Neurol.* 2018;9:580.
- 9.Gasca-González OD, Pérez-Cruz JC, Baldonchi M, Macías-Duvinhau MA, Delgado-Reyes L. Neuroanatomical basis of Wallenberg syndrome. *Cir Cir.* 2020;88(3):376-82.
- 10.De Cockler LJ, Geerlings ML, Hartkamp NS, Groof AM, Mali WP, Van der Graaf Y, et al. Cerebellar infarct patterns: The SMART-Medea study. *Neuroimage Clin.* 2015;8:314-21.
- 11.Moreau F, Patel S, Lauzon ML, McCreary CR, Goyal M, Frayne R, et al. Cavitation after acute symptomatic lacunar stroke depends on time, location, and MRI sequence. *Stroke.* 2012;43(7):1837-42.
- 12.Di Stefano G, Di Lionardo A, Di Pietro G, Truini A. Neuropathic Pain Related to Peripheral Neuropathies According to the IASP Grading System Criteria. *Brain Sci.* 2020;11(1).
- 13.Alafaci C, Granata F, Cutugno M, Marino D, Conti A, Tomasello F. Glossopharyngeal neuralgia caused by a complex neurovascular conflict: Case report and review of the literature. *Surg Neurol Int.* 2015;6:19.